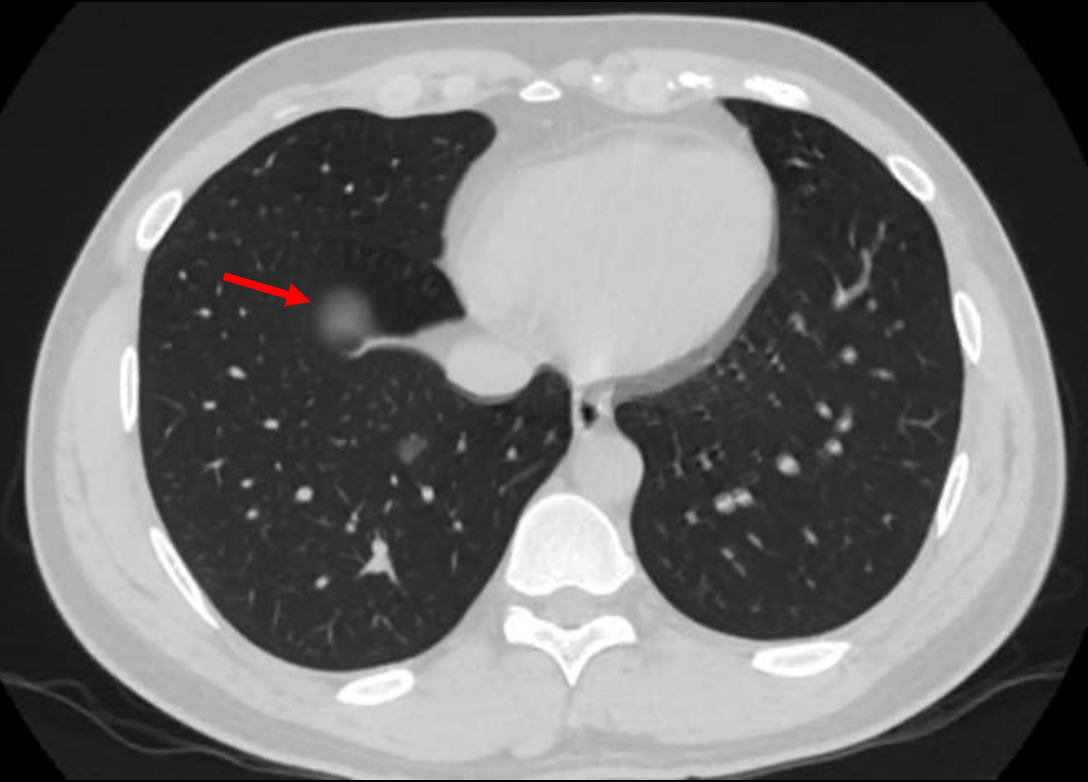


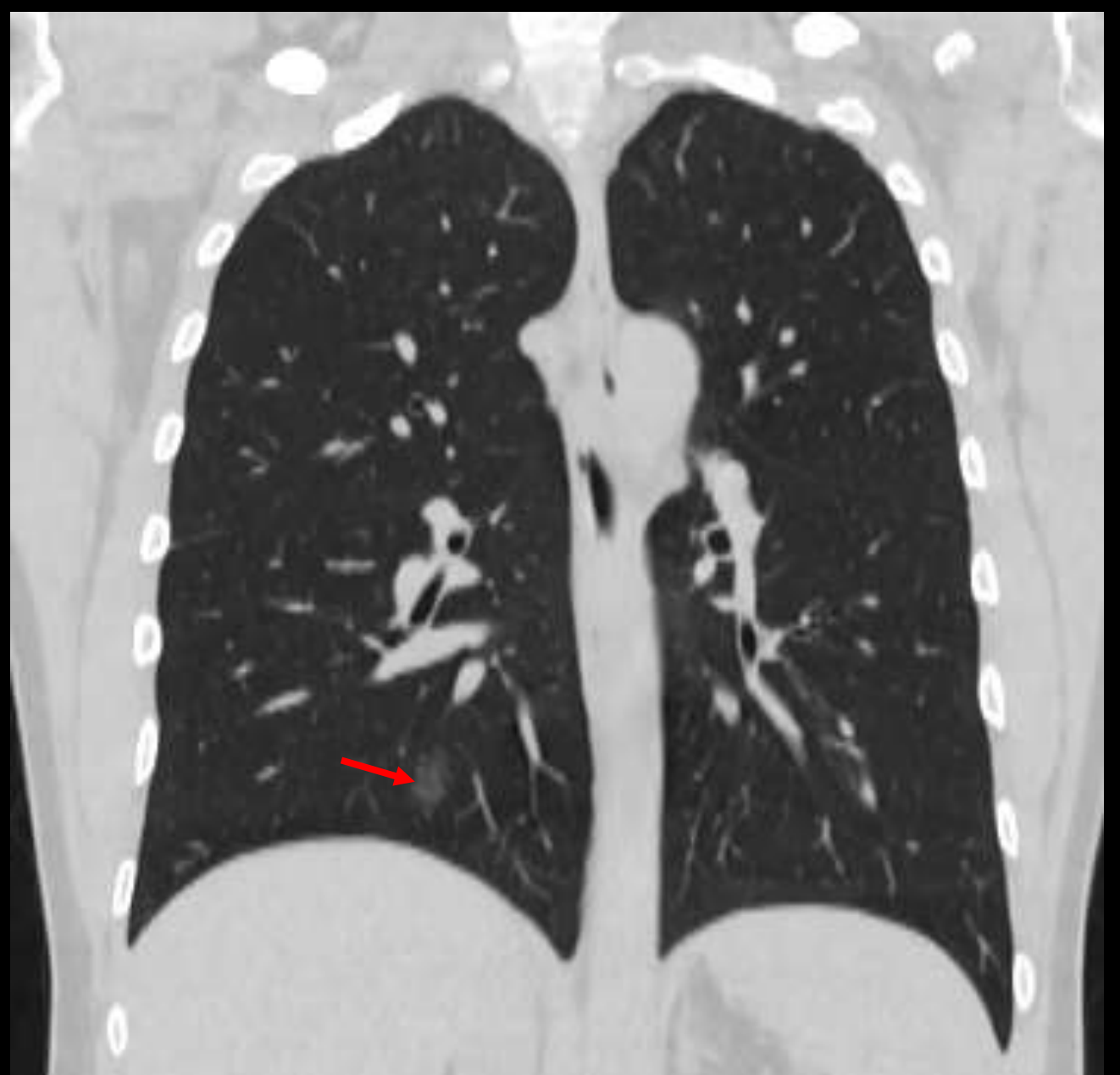# PRIMJERI CT PROMJENA U PLUĆIMA KOD COVID-19 POZITIVNIH PACIJENATA

Saška Grupković, Marija Perunović - Eraković, Sanja Vrbica  
Opšta bolnica Nikšić

# SLUČAJ 1:

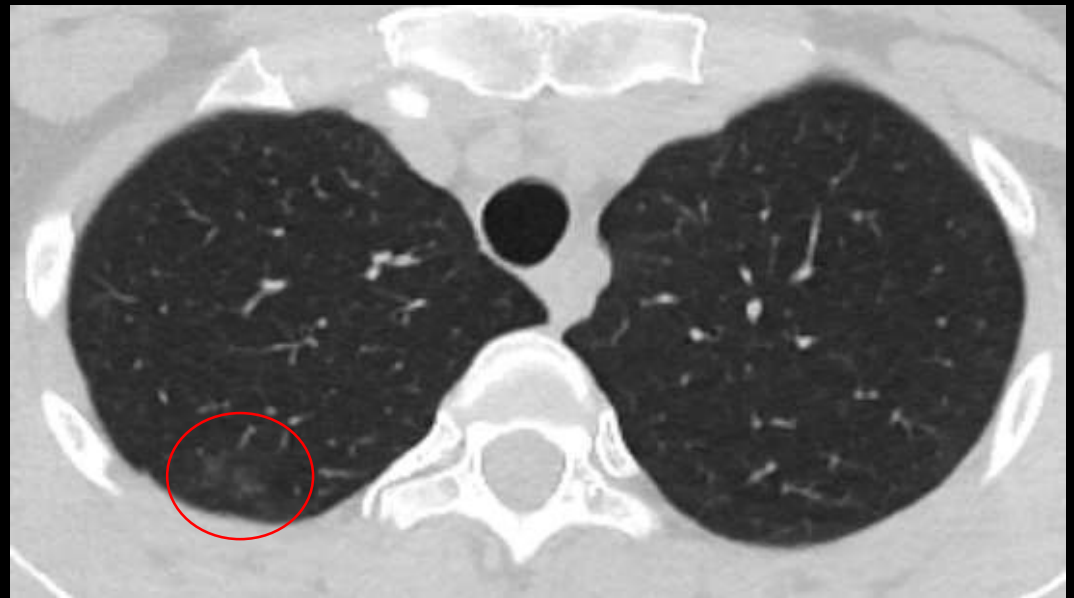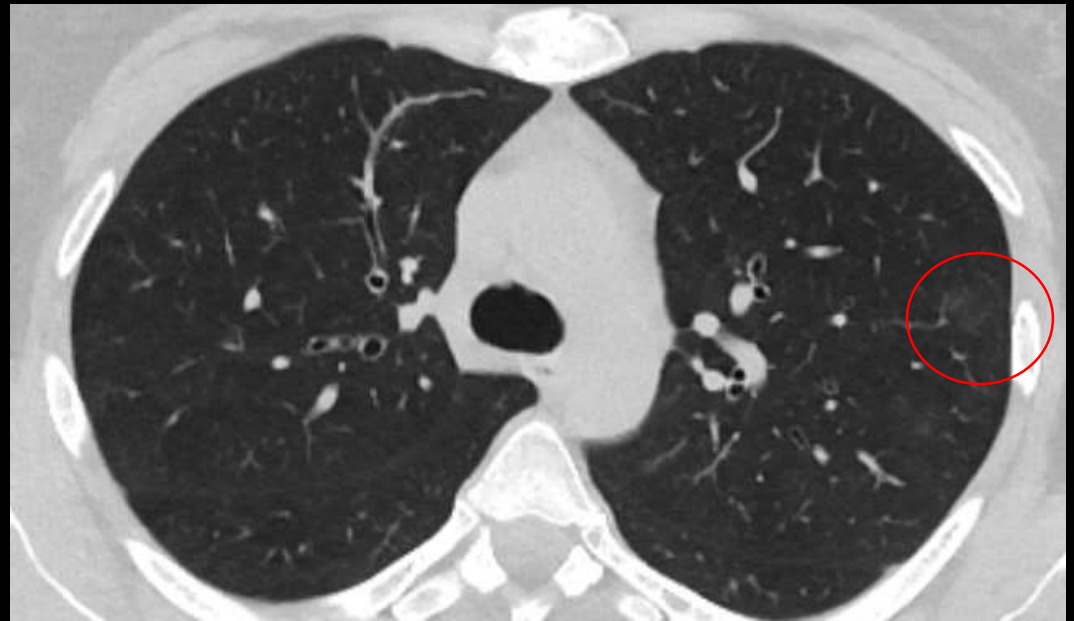

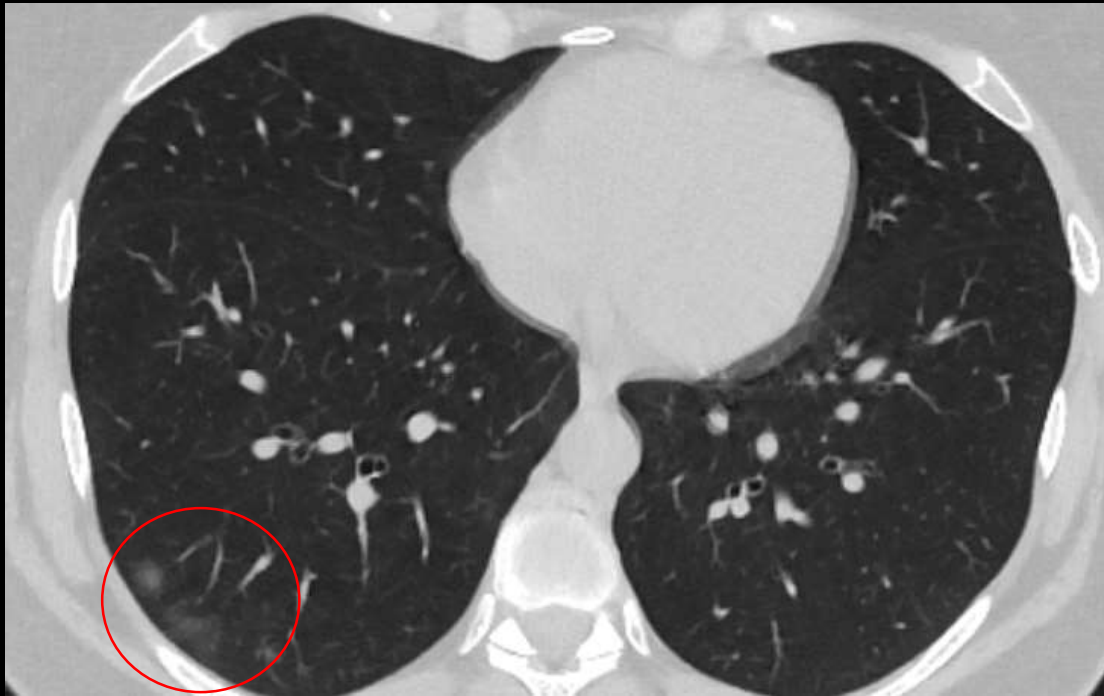
- Mušakarac, 26 godina
- Desno u donjem reznju nepravilna zona denziteta mlijecnog stakla

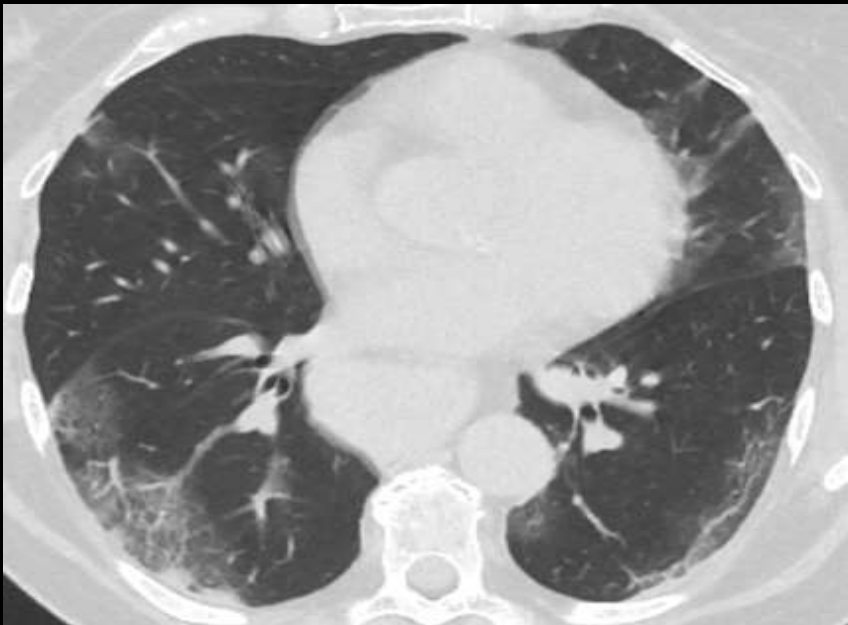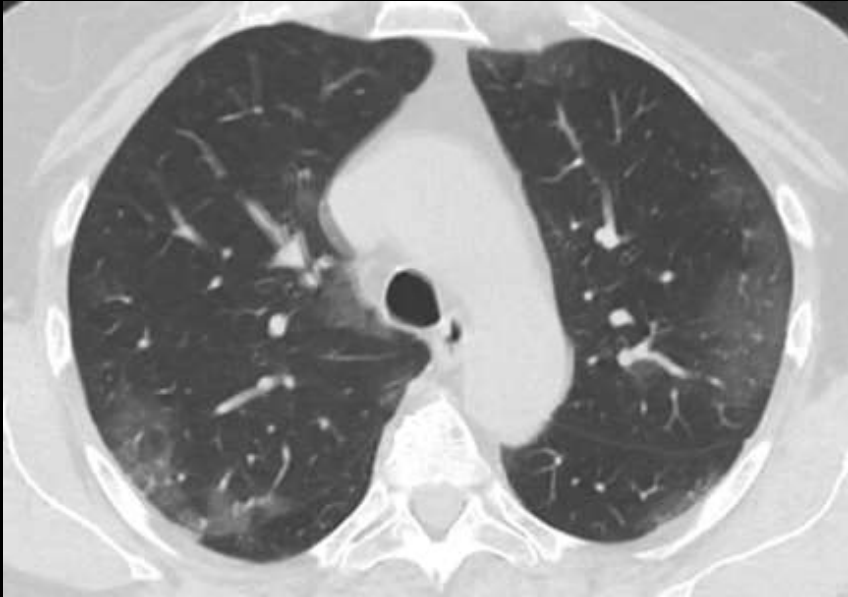


## SLUČAJ 2:

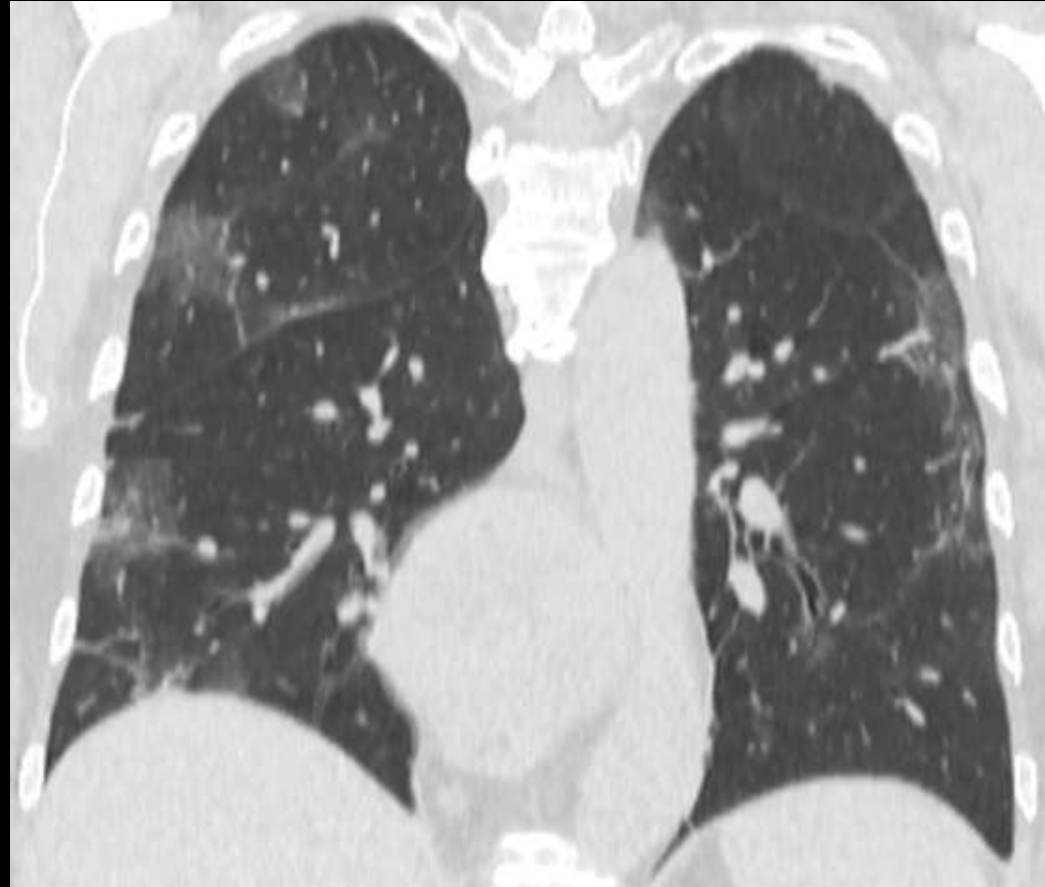- Žena, 37 godina
- Obostrano periferno subpleuralno zone GGO



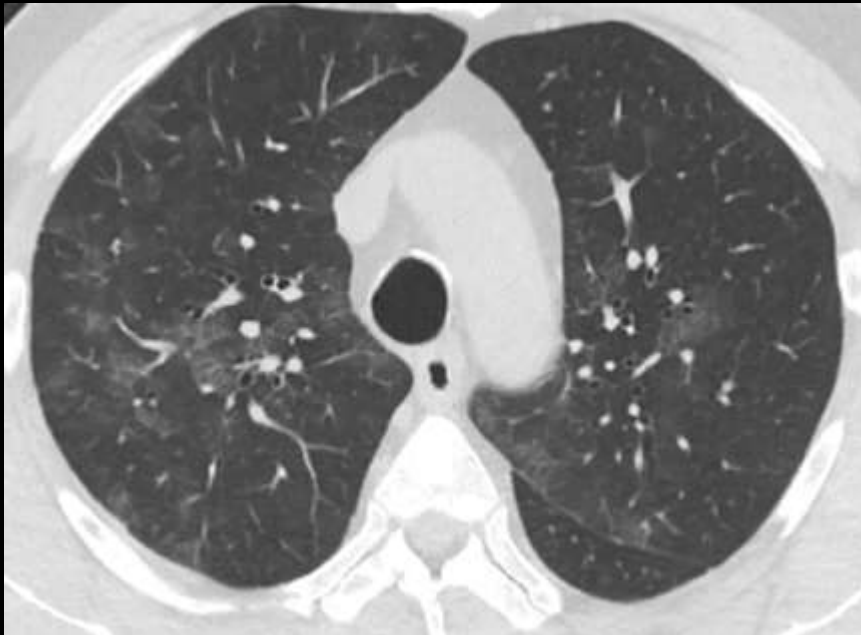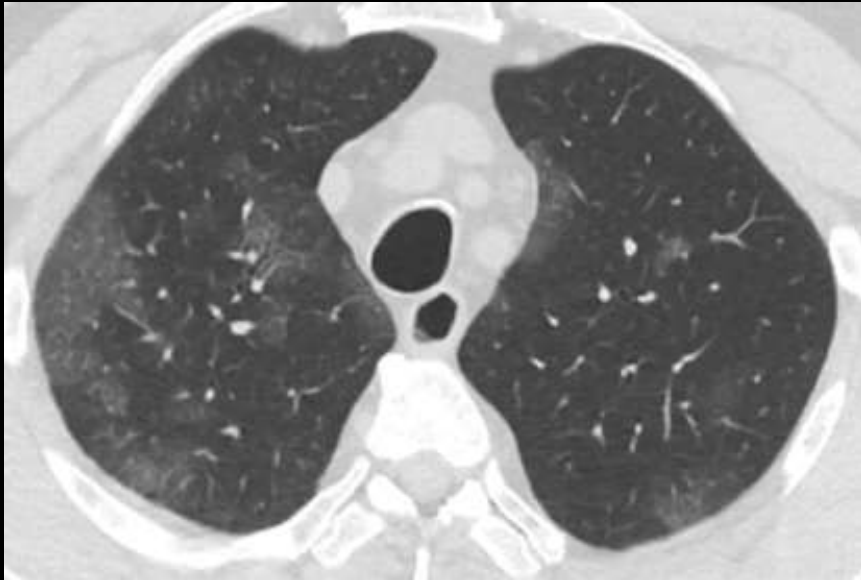# SLUČAJ 3:



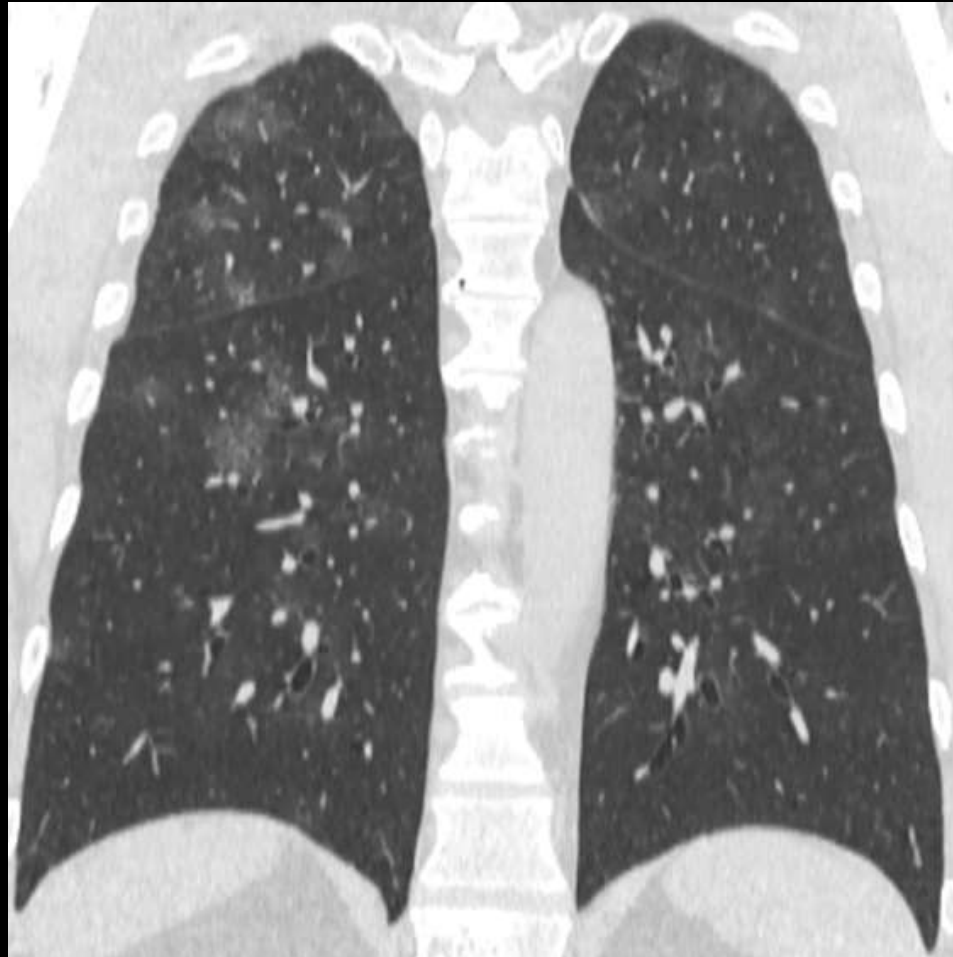- Žena, 60 godina.
- Obostrano multilobarno, dominantno periferno, zone GGO sa manjim subpleuralnim konsolidacijama desno u donjem režnju i subpleuralnim trakama lijevo



## SLUČAJ 4:

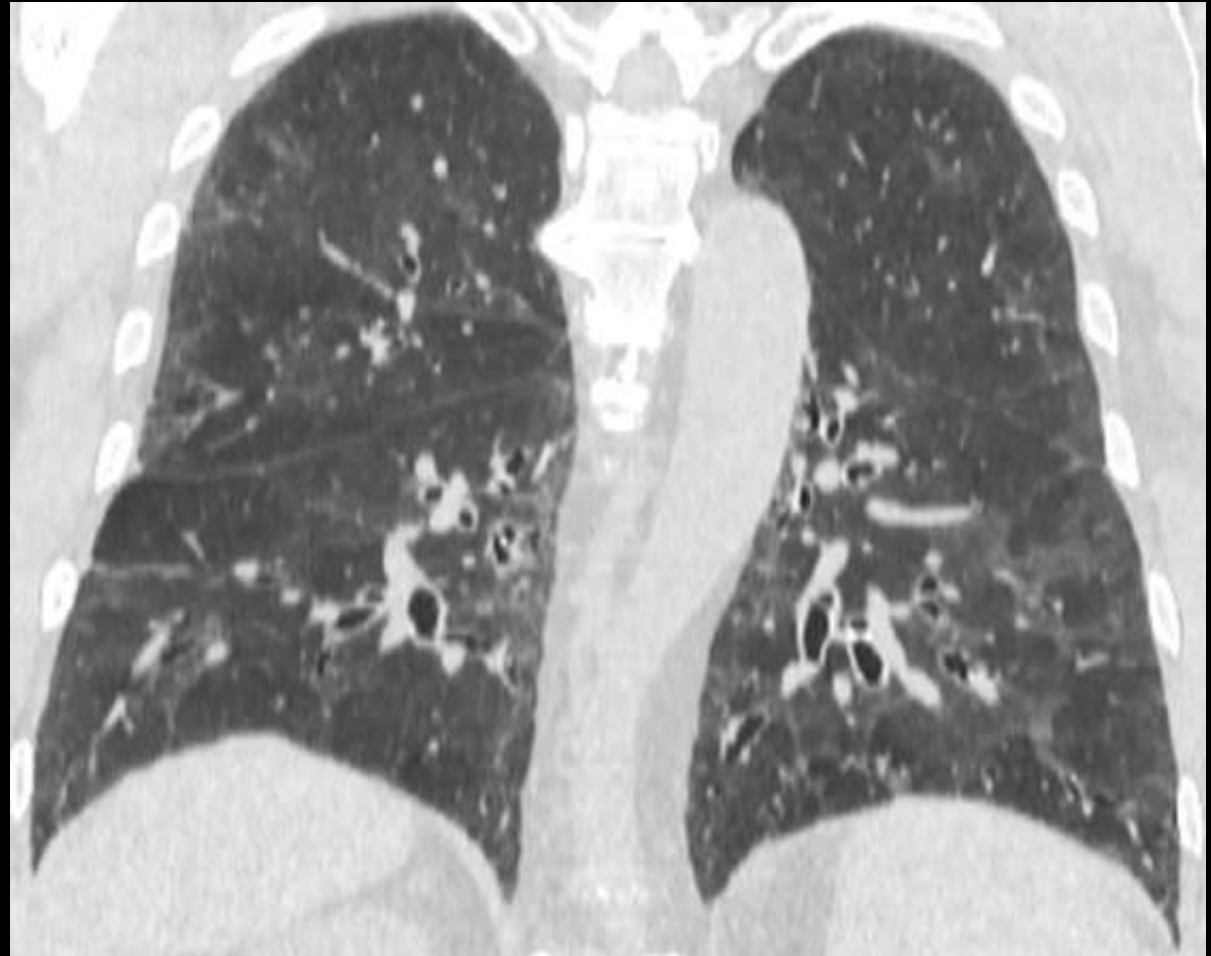
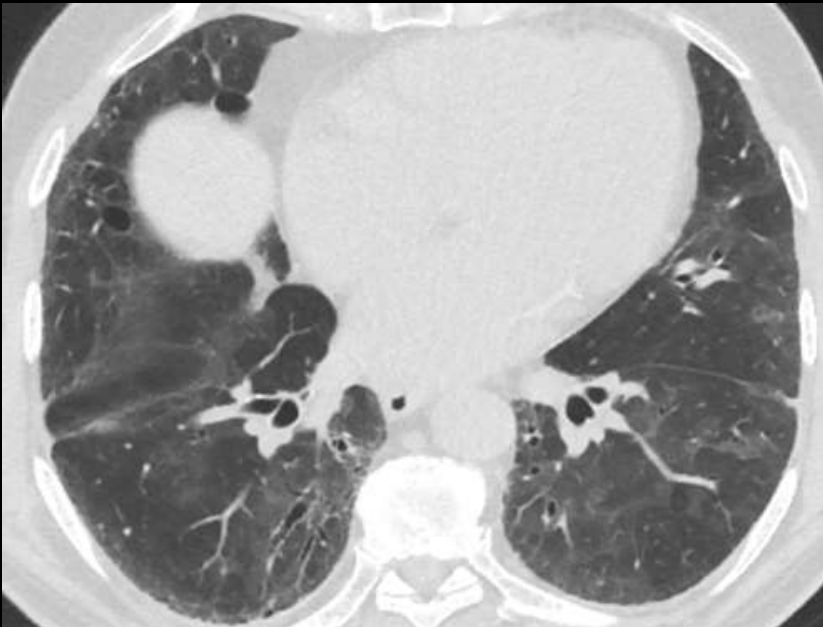
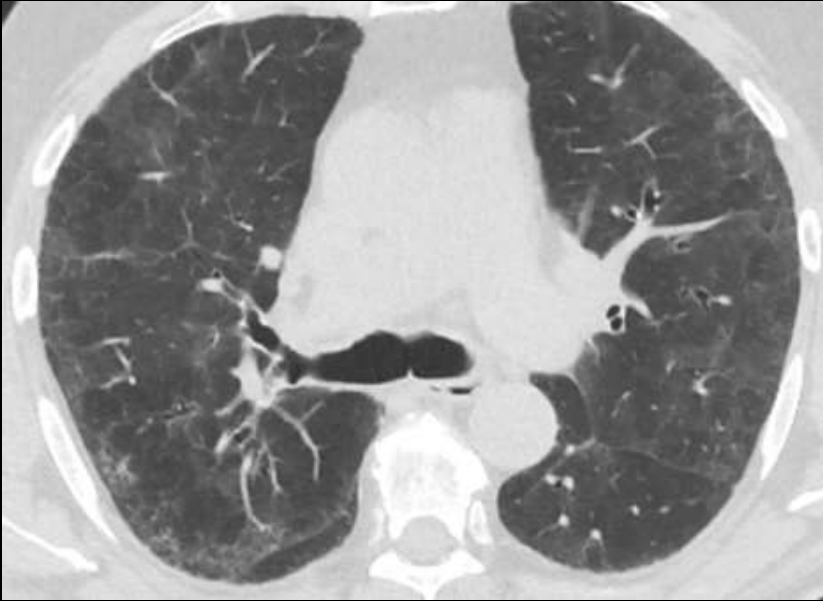- Muškarac, 61 godina.
- Multipli bilateralni GGO sa perihilarnom i perifernom distribucijom



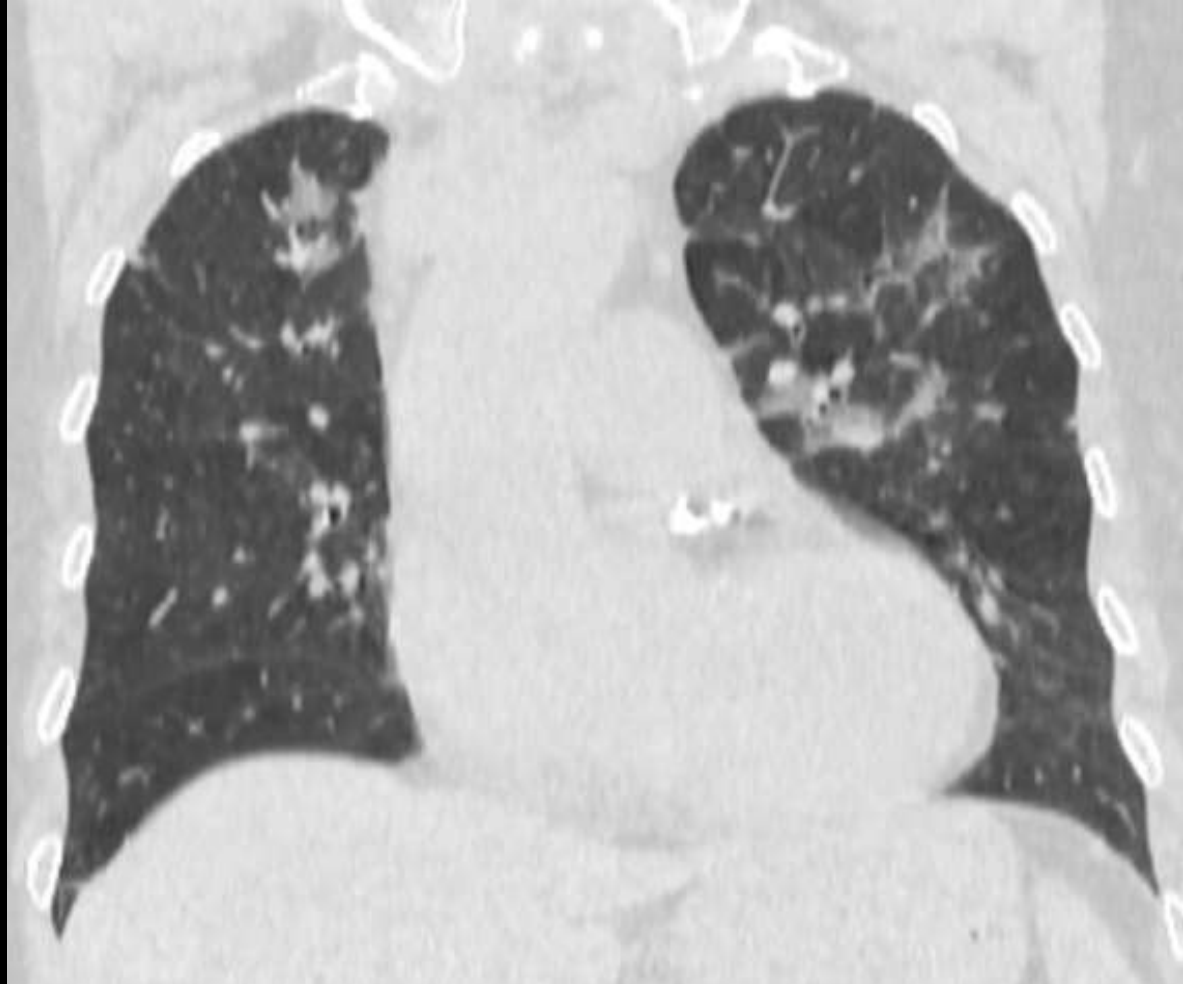
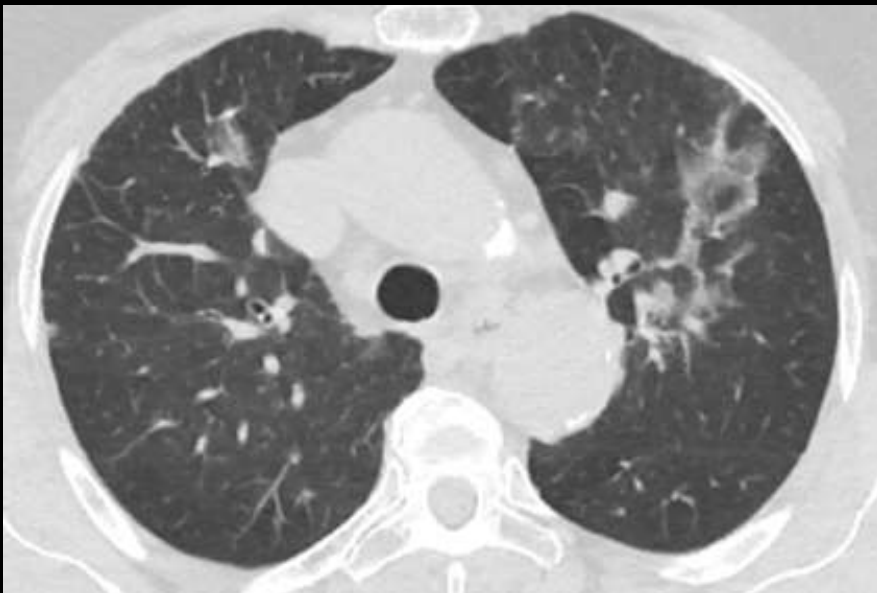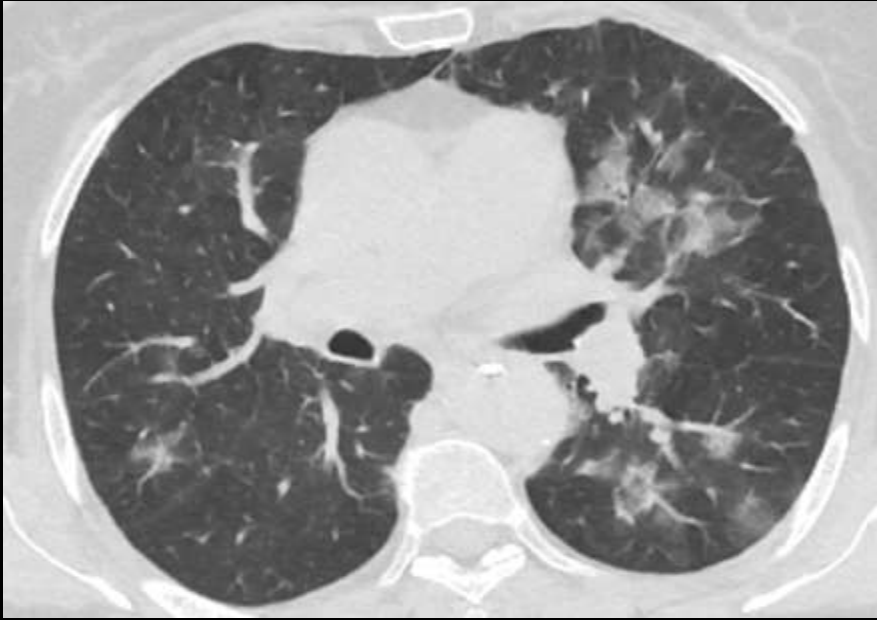
# SLUČAJ 5:

- Muškarac 71 godina.
- Multiple zone GGO sa deformisanim intersticijumom i bazalno obostrano trakcionim



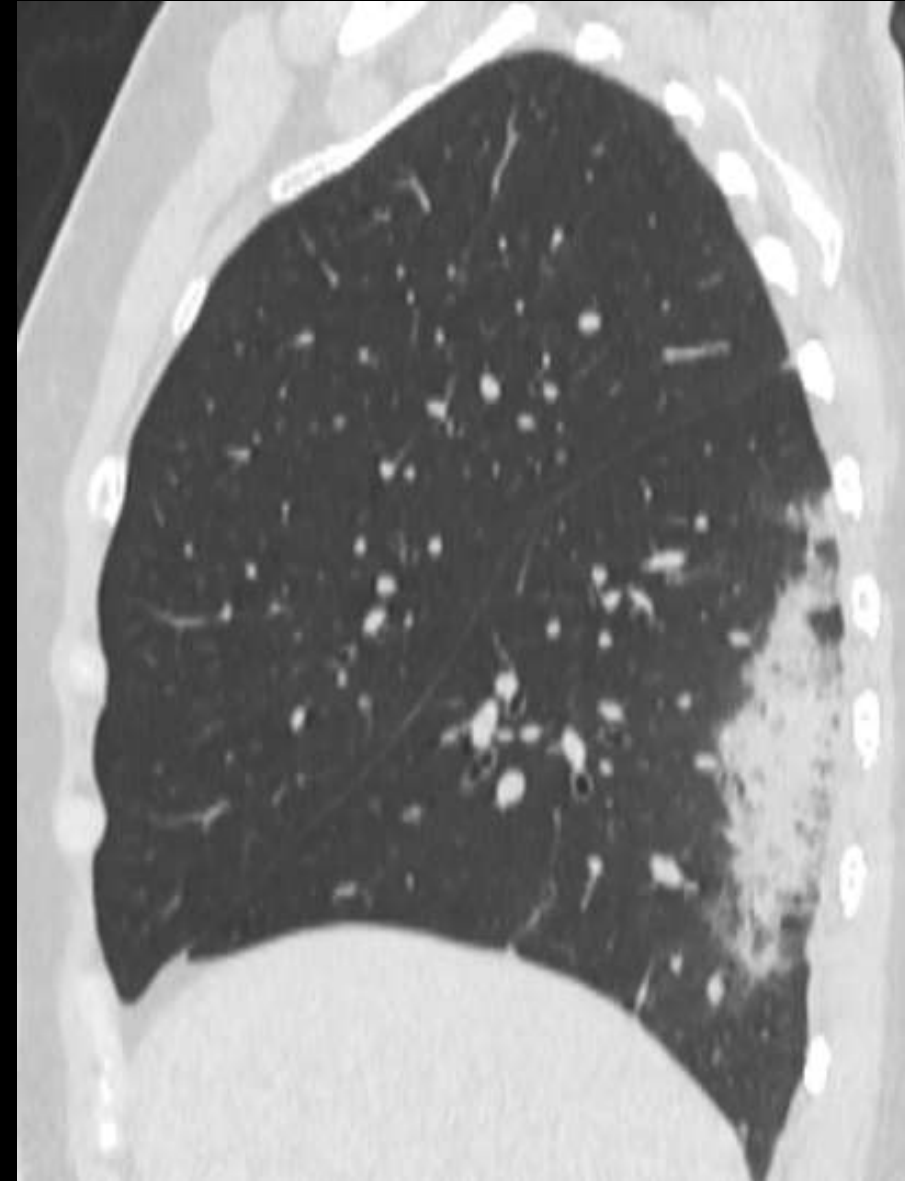
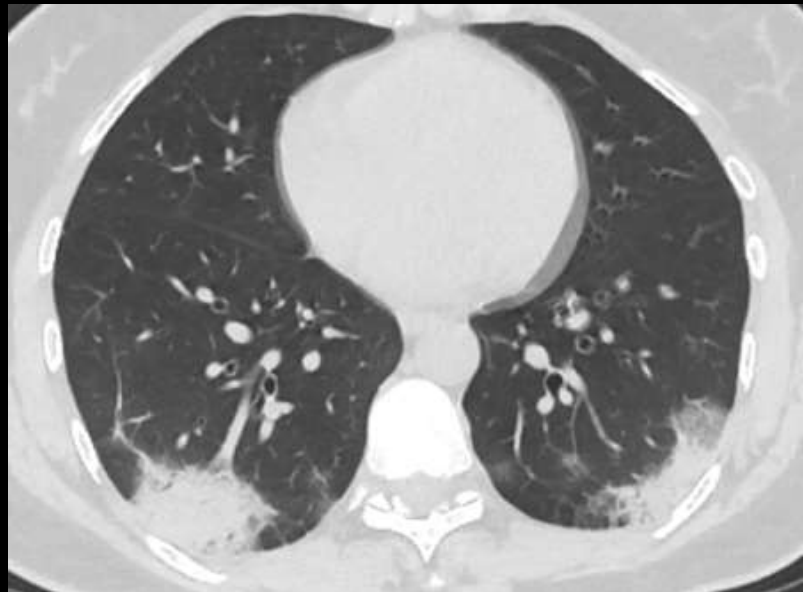
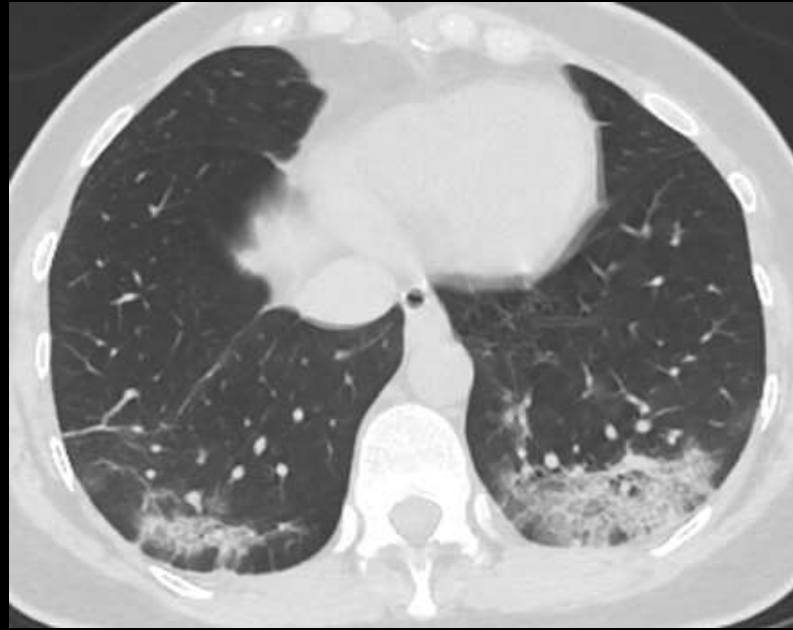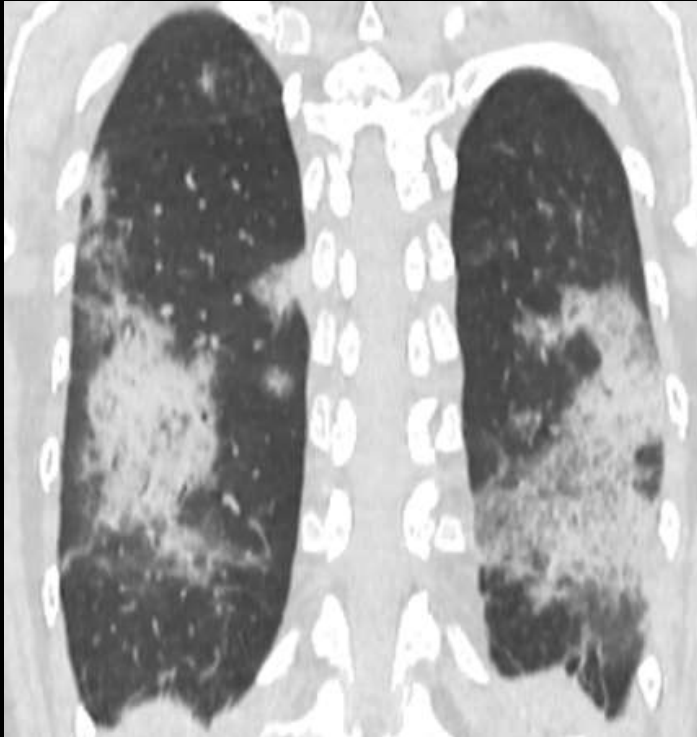
## SLUČAJ 6:

- Žena, 69 godina
- Obostrano dominantno lijevo multiple zone GGO nespecifične distribucije.



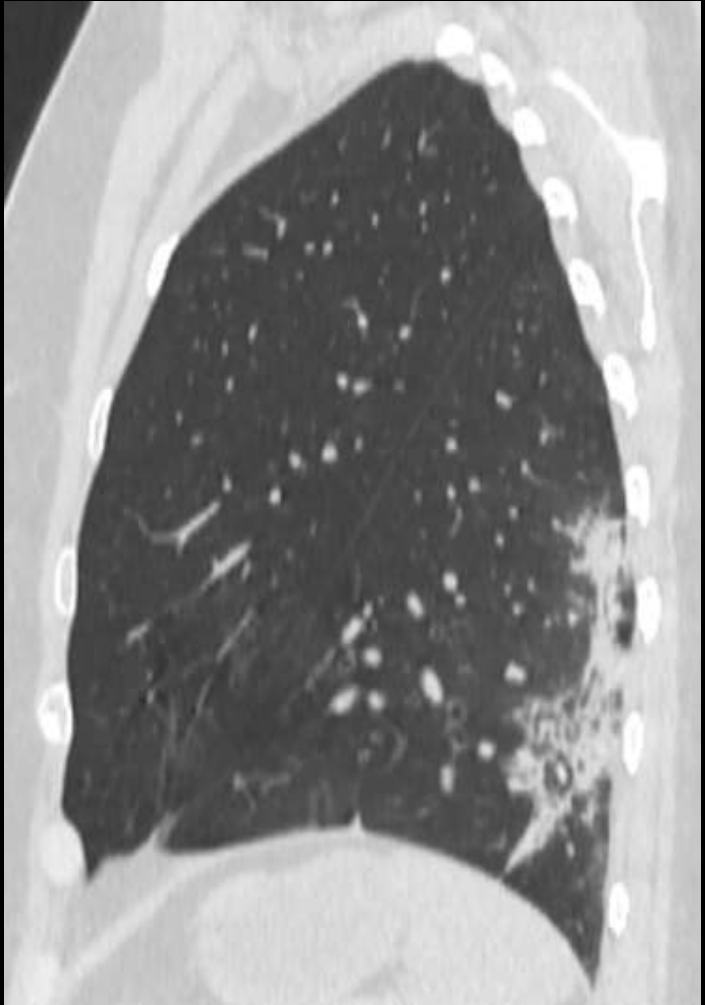
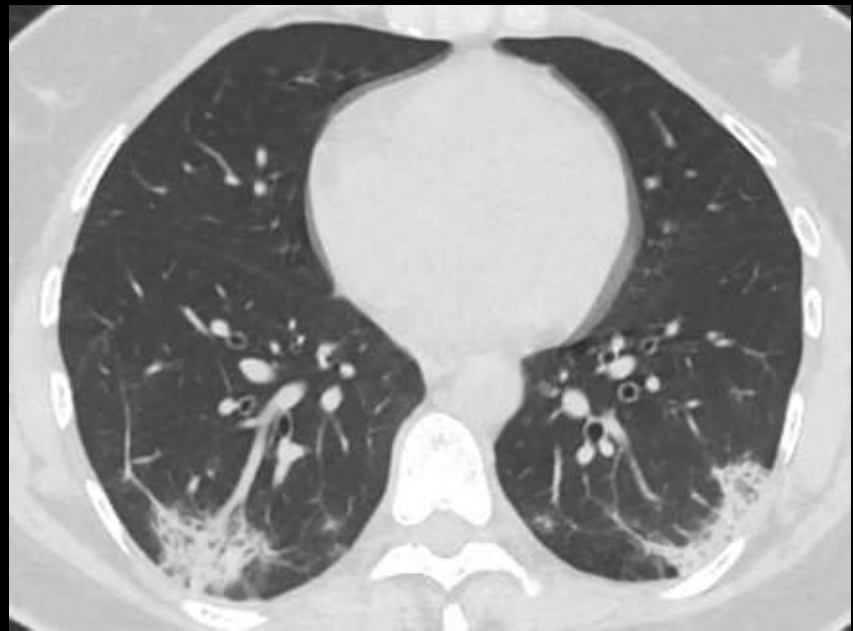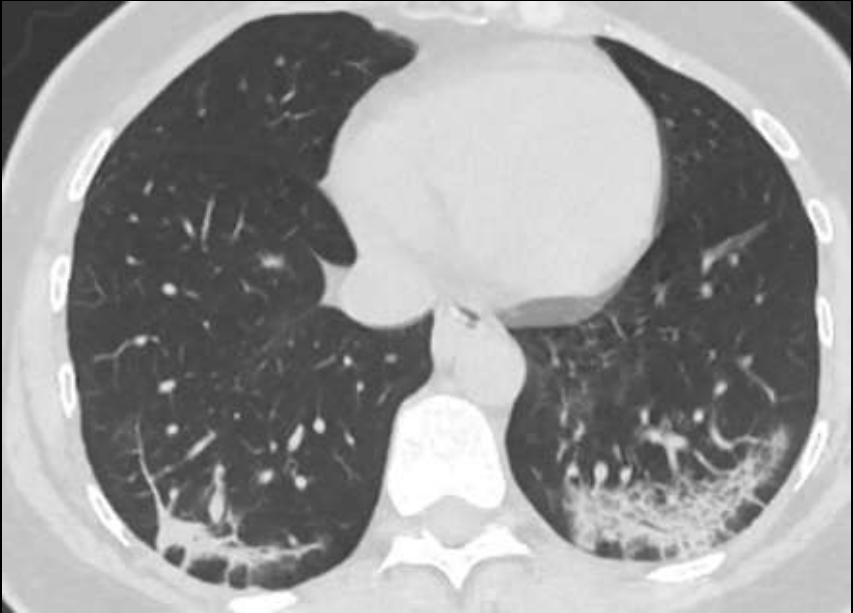
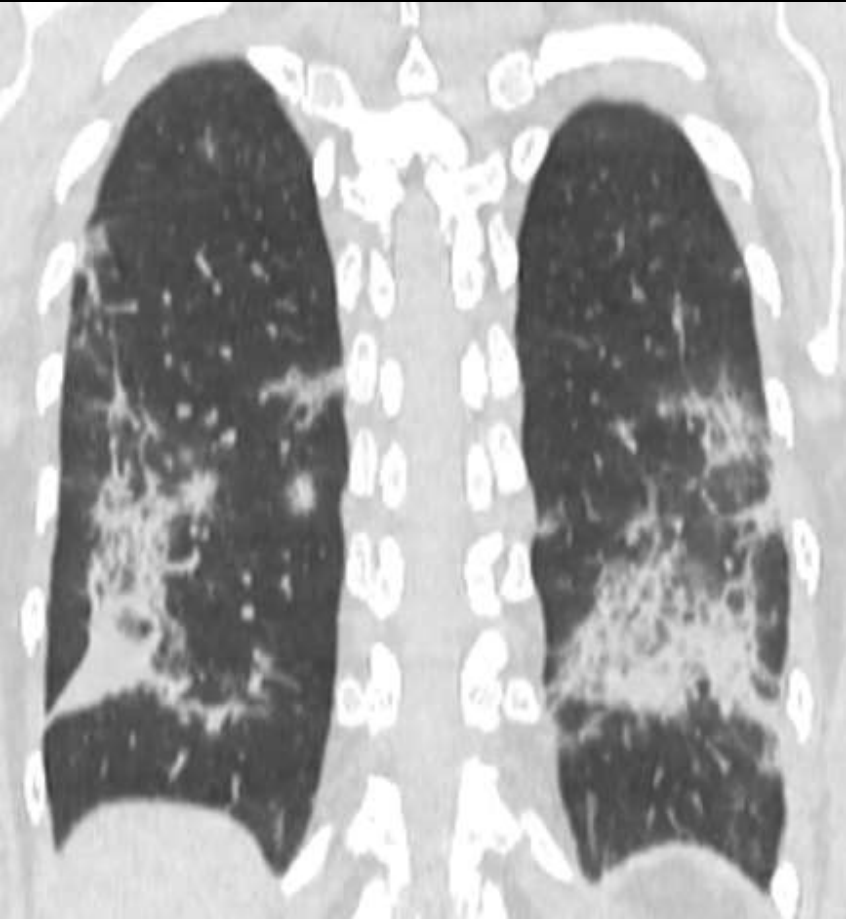
# SLUČAJ 7:

- Žena, 46 godina.
- Obostrano u donjim režnjevima subpleuralno posteriorno konsolidacije uz manje zone GGO i „crazy paving“ uzorak u donjem lijevom režnju.

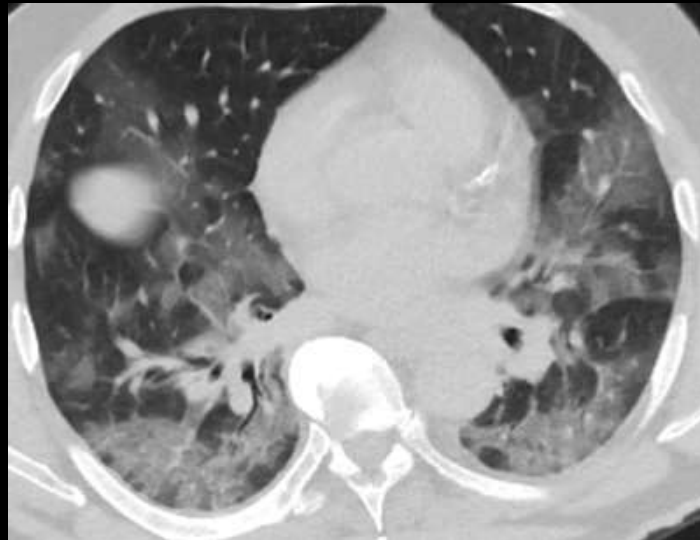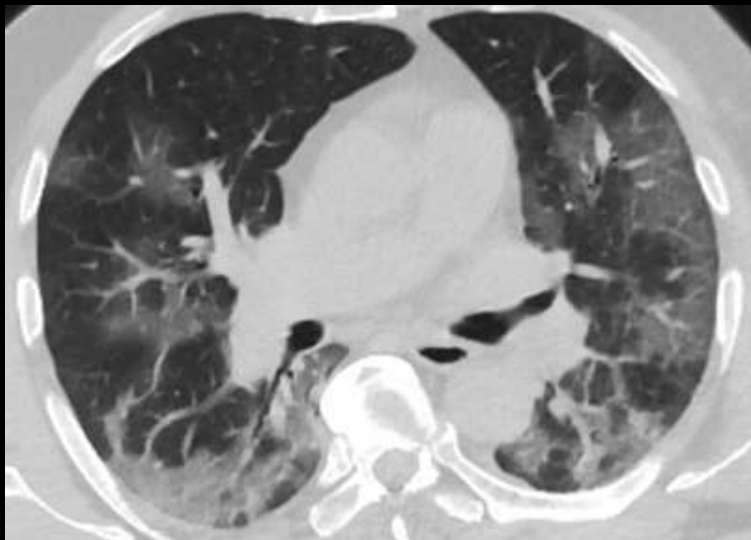

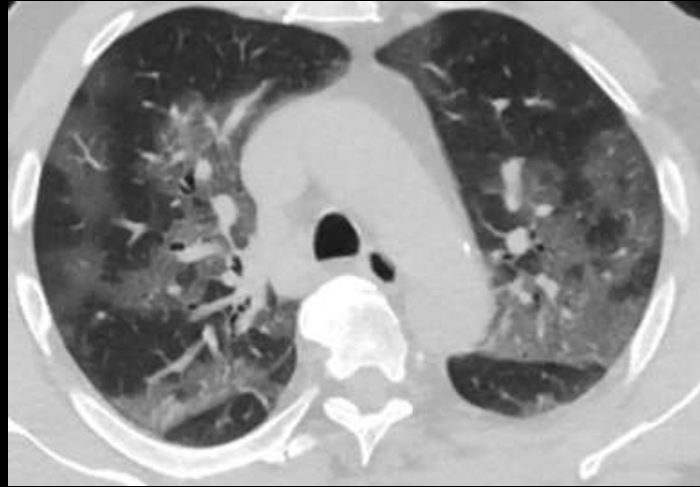
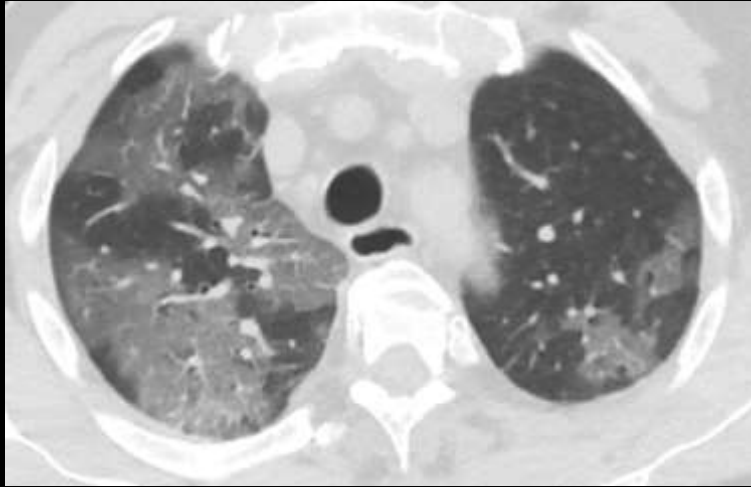

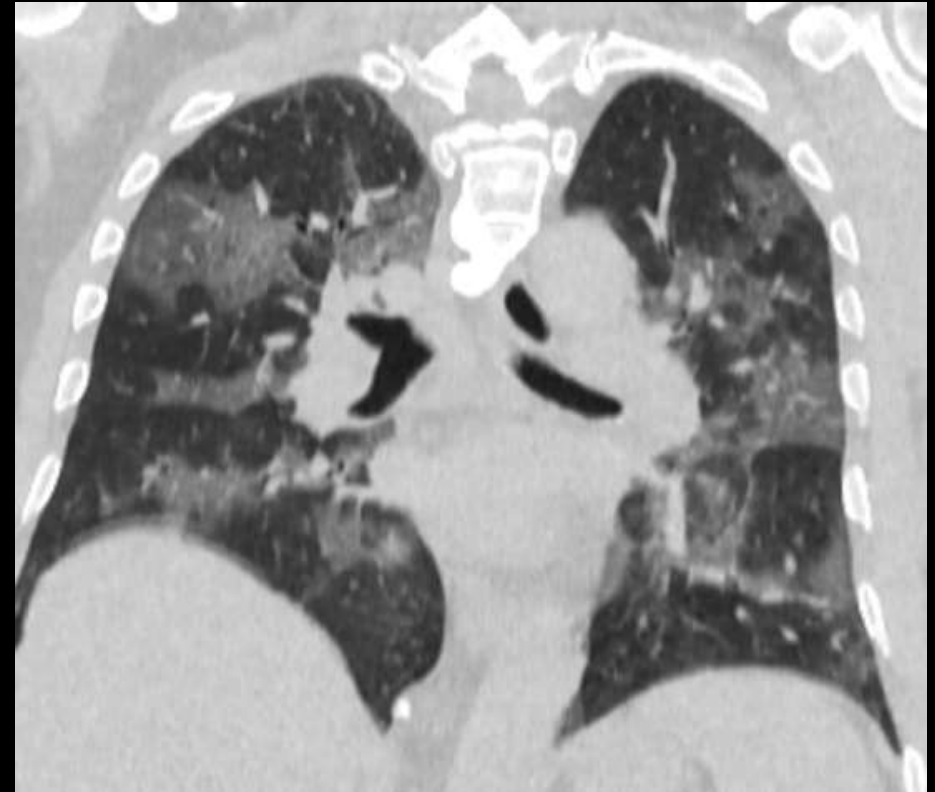- KONTROLA nakon 6 dana pokazuje laku regresiju promjena

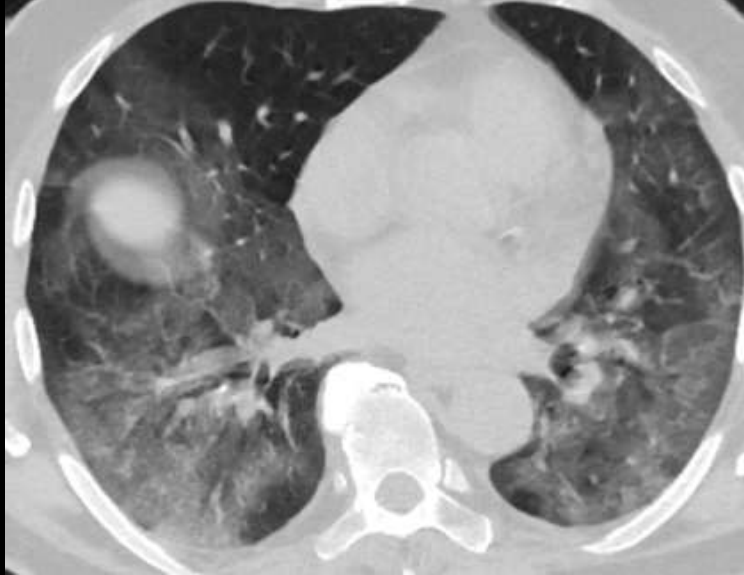
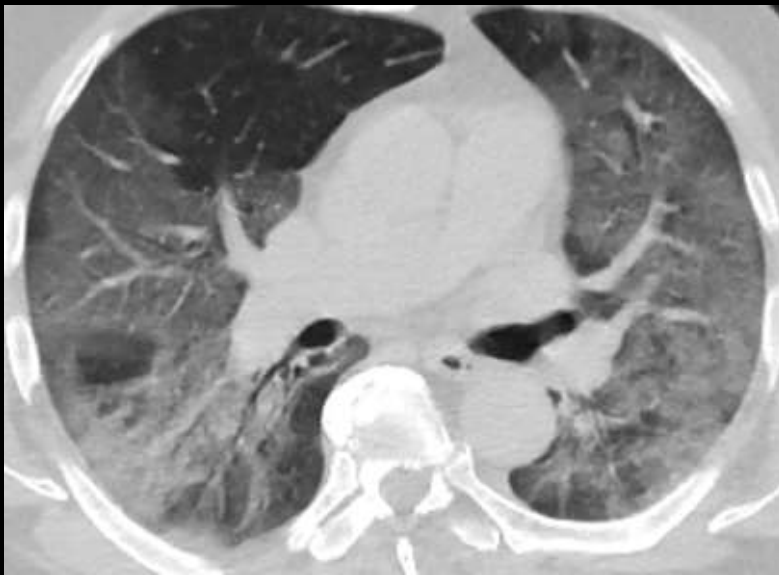
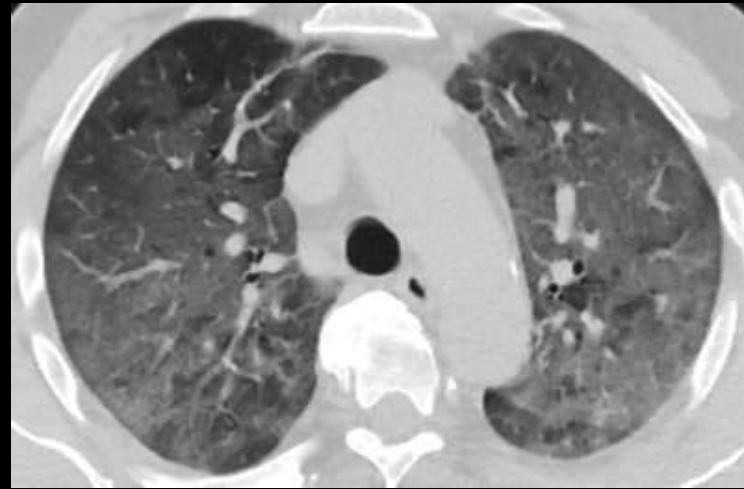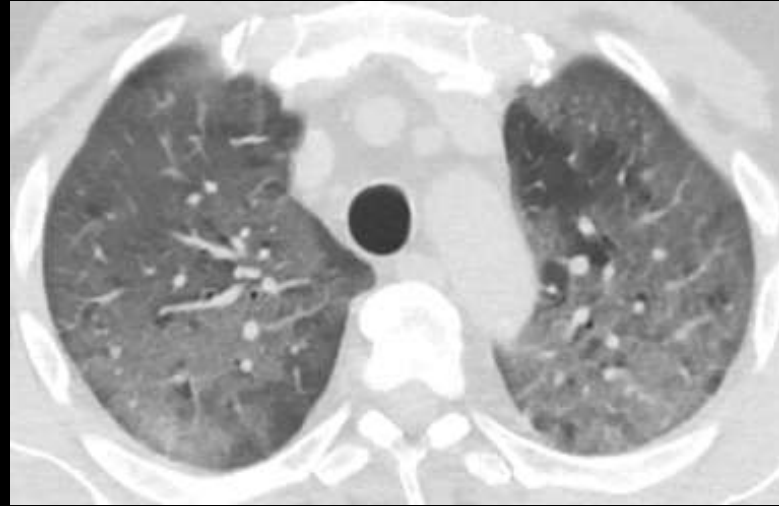# SLUČAJ 8:



- Muškarac, 63 godine
- Obostrani multipli ekstenzivni GGO





- Kontrola nakon 7 dana – progresija promjena sa difuznim GGO

